

A Revolutionary Advance in Skin Closure Compared to Current Methods

Angela Piñeros-Fernandez, MD¹ Lisa S. Salopek, LVT, RLAT,²
Pamela F. Rodeheaver, BA,³ David B. Drake, MD,⁴
Richard F. Edlich, MD, PhD,⁵ & George T. Rodeheaver, PhD⁶

¹Research Assistant in Plastic Surgery; ²Registered Laboratory Animal Technician;

³Research Assistant in Plastic Surgery; ⁴Associate Professor of Plastic Surgery;

⁵Distinguished Professor of Plastic Surgery, Biomedical Engineering, and Emergency Medicine, University of Virginia Health System, Charlottesville, VA, Director of Trauma Prevention, Education and Research, Trauma Specialist, LLP, Legacy Emanuel Hospital, Portland, Oregon, USA; ⁶Distinguished Research Professor of Plastic Surgery, University of Virginia Health System, Charlottesville, Virginia, USA

Address all correspondence to George T. Rodeheaver, Department of Plastic Surgery, University of Virginia Health System, P.O. Box 801351, Charlottesville, VA 22908-1351; gtr3s@virginia.edu

ABSTRACT: Six pigs were used to evaluate the influence of three separate modalities on contaminated wounds. Full-thickness skin wounds on the abdomen were contaminated with 10^4 or 10^5 *Staphylococcus aureus* and then closed with one of three methods. The three closure modalities included (1) a new absorbable staple (Inorb™) placed in the subcuticular tissue, (2) a braided Vicryl™ suture, and (3) percutaneous metal staples. Any foreign body material implanted in tissue increases the risk of infection at that site. Wound closure always involves the use of a foreign body. Historically, sutures have been the primary material used to close tissue. The newer synthetic sutures are significantly more biodegradable and cause less infection than sutures composed of protein, such as silk and catgut. Metal staples are also associated with a low risk of infection. Recently, Incisive Surgical, Inc. (Plymouth, Minnesota) has developed an absorbable polymer staple specifically for subcuticular skin closure. The purpose of this study was to compare the new Inorb™ staple to both an absorbable polymer suture and a metal staple.

Wound infection was assessed 7 days after closure by clinical signs and quantitative bacterial swabs. The results demonstrated that wounds closed with Inorb™ staples had the lowest incidence (33%) of infection, followed by percutaneous metal staples (44%). All wounds (100%) closed with Vicryl™ suture became infected. The incidence of wound infection directly correlated with the level of quantitative bacterial count at analysis. The Inorb™ staple was associated with significantly reduced closure time, less inflammation and infection, and better aesthetic result compared to Vicryl™. Compared to metal staples, the Inorb™ subcuticular staplers demonstrated comparable closure time without the need for later staple removal. In conclusion, the closure of contaminated wounds with the Inorb™ staples is a superior choice to Vicryl™ suture because they have a significantly ($p = 0.009$) lower incidence of infection. The Inorb™ staple is a revolutionary advance in subcuticular skin stapling.

KEYWORDS: Inorb™ staples, Vicryl™ suture, skin staple, *Staphylococcus aureus*, subcuticular, wound infection, wound closure speed, aesthetic result

Received July 22 2005 / Accepted August 22 2005

I. INTRODUCTION

The revolutionary INSORB® Subcuticular Skin Stapler is designed to combine the cosmetic result of absorbable sutures with the rapid closure times associated with metal skin staplers, while eliminating the need for metal staple removal postoperatively (Fig. 1). The patented INSORB®20 Subcuticular Skin Stapler (Incisive Surgical Inc.,® Plymouth, Minnesota) is a sterile, single-patient-use device that deploys up to 20 staples, which is sufficient to close a 17 cm incision. The INSORB® Absorbable staple is composed of a copolymer that is predominantly polylactide, which is absorbed over a period of a few months. In 10 weeks, the mass of this staple is approximately one-half of its original size.

This stapler uses a novel method of dermal closure that presents the dermis and then precisely places an absorbable staple in a horizontal, subcuticular, and interrupted manner to provide a secure, well-approximated everted dermal closure. The staple design features a U-shaped curvature with cleats at the two distal ends to secure the subcuticular tissue.

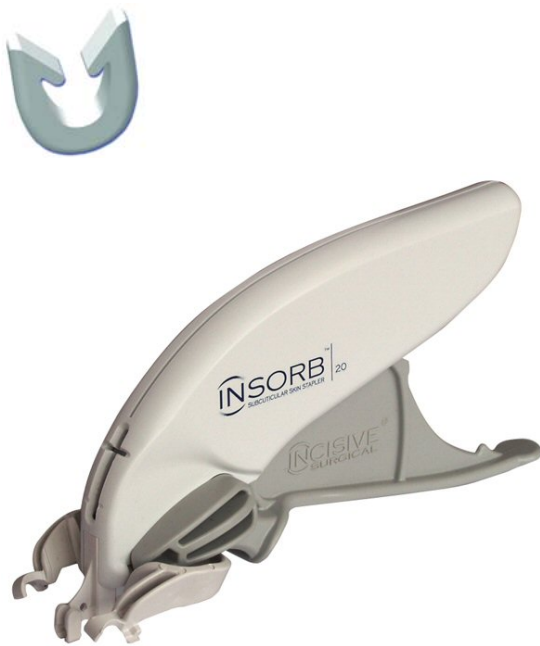

FIGURE 1. Inso**rb**™ Staple and Stapler.

Any foreign body material implanted in tissue increases the risk of infection at that site.¹ The degree of risk is proportional to the magnitude of chemical and physical inflammation induced by the foreign body.² Nonporous, chemically inert implants are the most biocompatible materials and are associated with a low risk of infection.³

Wound closure always involves the use of a foreign body. Historically, sutures have been the primary material used to close tissue. With advances in polymer chemistry, the current synthetic sutures are significantly more biocompatible and potentiate less infection than earlier sutures composed of protein, such as silk and catgut.⁴ In addition to sutures, the use of metal staples for wound closure has increased dramatically. By being nonporous and inert, these metal staples are associated with a low risk of infection.⁵

The purpose of this study was to compare the new synthetic Inso**rb**™ staple to either a braided synthetic suture of a similar polymer or to a metal staple used percutaneously in their ability to potentiate wound infection.

II. MATERIALS AND METHODS

II.A. Wound Closure Devices

In this study, three types of wound closure devices were used:

1. **INSORB™ Subcuticular Skin Stapler.** The stapler contains 20 individual, horseshoe-shaped staples. Each staple is nominally 5 mm long × 3.5 mm wide × 0.7 mm thick. The staple is composed of an absorbable copolymer of predominantly polylactide and a lesser component of polyglycolide. The staplers were supplied by the manufacturer as sterile, quality-assured product. In this study, Lot #050301 was used. Closure with Inso**rb**™ staples was accomplished by having an assistant approximate and elevate the skin edges within the stapler device using two Adson forceps, while the primary surgeon fired the stapler.

2. **Coated Vicryl™ Suture** (Ethicon, Inc., Somerville, New Jersey). Vicryl suture is a braided suture composed of filaments of an absorbable copolymer of 90% polyglycolic acid and 10% lactic acid. In this study, size 3/0 suture swaged to an X-1 cutting needle (Lot #TJ8467) was used. The suture was obtained from a commercial source.
3. **Multifire Premium™ Skin Stapler** (Auto Suture™, Div. U.S. Surgical, Div. Tyco Healthcare, Norwalk, Connecticut) forms the stainless steel staple one at a time with each depression of the stapler handle. The staple legs penetrate the skin on each side of the closed incision and then are formed into a rectangle in the tissue, which holds the wound together. The staplers were obtained from a commercial source. In this study, Lot #N4M268 was used.

prepped for surgery with three alternating regimens of iodophor antiseptic and 70% alcohol. The abdomen was isolated with sterile drapes.

A sterile surgical marker was used to mark nine symmetrically placed longitudinal skin incisions. The incisions were in three rows of three columns on the abdomen (Fig. 2). Each incision was made with a scalpel and was 4 cm in length and full thickness. Hemostasis was achieved with sterile gauze and pressure.

Each incision was contaminated by adding 0.05 mL of saline containing either 10^4 or 10^5 *S. aureus*. Wounds on three pigs received 10^4 and those on the other three pigs received 10^5 . The contaminating fluid was allowed to set for 30 minutes before wound closure occurred.

Three wounds on each pig were closed with each closure material. The wounds were systematically ran-

II.B. Experimental Design

Six pigs were used. On each abdomen, 9 skin incisions were created. The wounds on three pigs were contaminated with 10^4 *Staphylococcus aureus* (*S. aureus*) (ATCC 12600) from the American Type Culture Collection (Rockville, Maryland), and those on the other three with 10^5 *S. aureus*. Thirty minutes after contamination, the wounds were closed with either Inisorb™ staples, Vicryl™ sutures, or skin staples. Seven days following closure, the wounds were assessed for edema, erythema, presence of purulent exudate, and number of bacteria remaining in the wound.

II.C. Surgical Model

Female, domestic, white pigs (40–60 kg) were anesthetized with an intramuscular injection of ketamine (6 mg/kg) and xylazine (2 mg/kg), intubated, and maintained on isoflurane/oxygen (~2%). The abdominal hair was clipped with electric shears and the skin depilated with a depilating cream. The skin was scrubbed with an iodophor scrub and then

Wound Placement on Abdomen

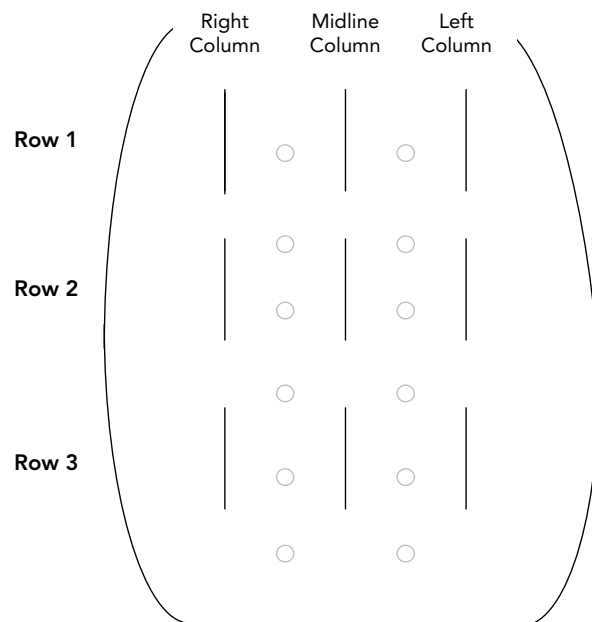


FIGURE 2. Location of 4 cm, full-thickness incisions on the abdomen of pigs. Each wound was labeled as animal #-row #-column-closure type, where: animal # = 1–6, row # = 1–3; column # = R (right), M (midline), or L (left); closure type = I (Inisorb™), V (Vicryl™), or S (metal staple).

domized to minimize the potential bias of anatomical location. Inisorb™ staples were placed at 8 mm intervals in the subcuticular tissue; four staples were used in each wound. Vicryl™ suture was used as a continuous running suture in the subcuticular tissue with 5 mm bites spaced at 5 mm intervals. Following subcuticular closure with Inisorb™ and Vicryl™, the surface of these wounds was reinforced with 1/8" wide wound closure tapes applied across the incision. Wounds closed with percutaneous metal staples received six evenly spaced staples and didn't require the additional tapes. Each wound was covered with an individual gauze pad, which was taped in place, and then a large pad was placed over all the wounds and held in place with circumferentially wrapped elastic bandage tape.

II.D. Bacterial Contamination

The organism used for this study was *S. aureus* 12600 from the American Type Culture Collection. Fresh isolates were maintained on tryptose blood-agar plates. Eighteen hours prior to the experiment, a single colony was transferred by wire loop to 25 mL of trypticase soy broth and shaken at 37°C in a water bath for 18 hours. The bacteria were collected by centrifugation and the pellet resuspended and recentrifuged twice in fresh, isotonic, sterile saline. After the second wash the pellet was resuspended in 2 mL of sterile, isotonic saline.

The resuspended bacteria were subjected to serial 1:10 dilutions in sterile, isotonic saline. From previous preparations under the same conditions, it was known which dilution tubes contained 10⁴ and 10⁵ colony-forming units (cfu) of *S. aureus*/0.05 mL. The actual number of bacteria in each dilution tube was confirmed by plating aliquots on blood-agar plates and counting the cfu after 24 hours of incubation at 37°C.

II.E. Analysis of Wound Infection at Day 7

Seven days following wound closure, the pigs were euthanized and their wounds exposed. Each wound

was assessed for its magnitude of inflammation by measuring the degree of edema, erythema, exudate in gauze and purulent exudate in wound on a scale of 0–3, where 0 = none, 1 = mild, 2 = moderate, and 3 = extreme. Wound temperature was rated as normal (–) or elevated (+), and wound dehiscence was rated as *yes* or *no* regardless of extent involved. Any other notes were also recorded.

After the qualitative assessment of wound appearance, the number of bacteria in each wound was quantitated with a standardized technique. An alginate-tipped swab was moistened with sterile saline and swabbed up the wound, rotated 180°, and swabbed back down the wound. The alginate tip was broken off in a sterile tube containing 5.0 mL of sterile, isotonic saline. The swab tip was vortexed for 1 minute to release bacteria, and the number of bacteria present was quantitated by standard serial dilution and plating techniques.

III RESULTS

Using the Inisorb™ stapler required a brief learning period. Once the tissue positioning and functioning of the stapler became familiar, wounds could be closed in much less time than that required to properly place a running suture. For these wounds, the time required for the Inisorb™ stapler was about 3 minutes, whereas the Vicryl™ suture required about 7 minutes. The Multifire Premium™ skin stapler was quicker than the Inisorb™ stapler and only required about 2 minutes.

When the Inisorb™ staples were properly placed, the wound was closed with good skin edge approximation and a slight eversion. Reinforcement with wound closure tapes was not required, but it was used in this study as a precaution because it involved animals.

Replacing a malpositioned Inisorb™ staple was not too much more difficult than replacing a metal staple. With the Inisorb™ staple, scissors were used to cut the staple at the bottom of its U shape, and then forceps were used to grab the barbed tips and pull each leg of the staple out of the tissue one at a time.

III.A. Wound Infection

Closure of contaminated wounds with braided Vicryl™ suture resulted in a significantly ($p = 0.009$) higher wound infection rate than those of wounds closed with Insorb™ staples or skin staples (Table 1, Fig. 3). In correlation with wound infection, the mean level of bacteria at day 7 in contaminated wounds closed with braided Vicryl™ sutures was significantly ($p \leq 0.02$) higher than that of similarly contaminated wounds closed with Insorb™ staples or skin staples (Table 1, Fig. 4).

The responses of the wounds were similar whether the level of wound contamination was 10^4 or 10^5 *S. aureus*.

The other parameters of wound infection correlated with the presence of purulent exudate (pus) and bacterial levels, which were used in conjunction to define which wounds were infected (Table 1).

There was a difference among the pigs as to their susceptibility to wound infection. In general, pigs 1 and 5 were more susceptible to infection than the other pigs. In all pigs, the wounds closed with

braided Vicryl™ suture became infected. However, for wounds closed with Insorb™ staples, the three of nine wounds that were contaminated with 10^4 *S. aureus* and became infected were all on pig 1, and the two of nine wounds that were contaminated with 10^5 *S. aureus* and became infected were both on pig 5. Similar results were obtained with the wounds closed with skin staples.

IV. DISCUSSION

All foreign bodies in tissue increase that tissue's risk for infection.¹ In general, braided or porous implants potentiate more infection than nonbraided or nonporous implants. The results of this study are in agreement with this expectation. The use of a braided Vicryl™ suture to close contaminated wounds resulted in a 100% wound infection rate. When similarly contaminated wounds were closed with nonporous devices, the incidence of wound infection was significantly reduced.

Although both staples produced similar low rates

TABLE 1. Analysis of Wound Infection at Day 7

Wound closure device	Inoculum	Signs of wound infection (mean values) ¹							Statistical significance
		Erythema (0-3)	Edema (0-3)	Exudate (gauze) (0-3)	Pus (wound) (0-3)	Dehisc. (%)	Temp. (%)	Bacteria (log/swab)	
Insorb™ Staple	10^4	0.3	0	0.2	0.3	0	0	2.99 ± 1.29	$p \leq 0.008$
Vicryl™ Suture		1.2	0.9	0.8	2.0	0	22	5.14 ± 0.74	
Premium™ Staple		0.4	0	0.2	0.4	0	11	3.30 ± 1.38	
Insorb™ Staple	10^5	0.3	0.6	0.6	0.7	0	0	3.89 ± 1.10	$p \leq 0.02$
Vicryl™ Suture		0.7	1.0	0.9	2.1	0	11	5.41 ± 0.34	
Premium™ Staple		0.4	0.2	0.4	1.0	0	0	3.90 ± 0.34	

¹For each bacterial inoculum, nine wounds were closed with each device. The results are reported as the mean score or percentage for each parameter.

²Once all the parameters were assessed, wound infection was defined as a wound containing pus with a bacterial load of ≥ 4.00 /swab and other signs of inflammation such as erythema, edema, etc.

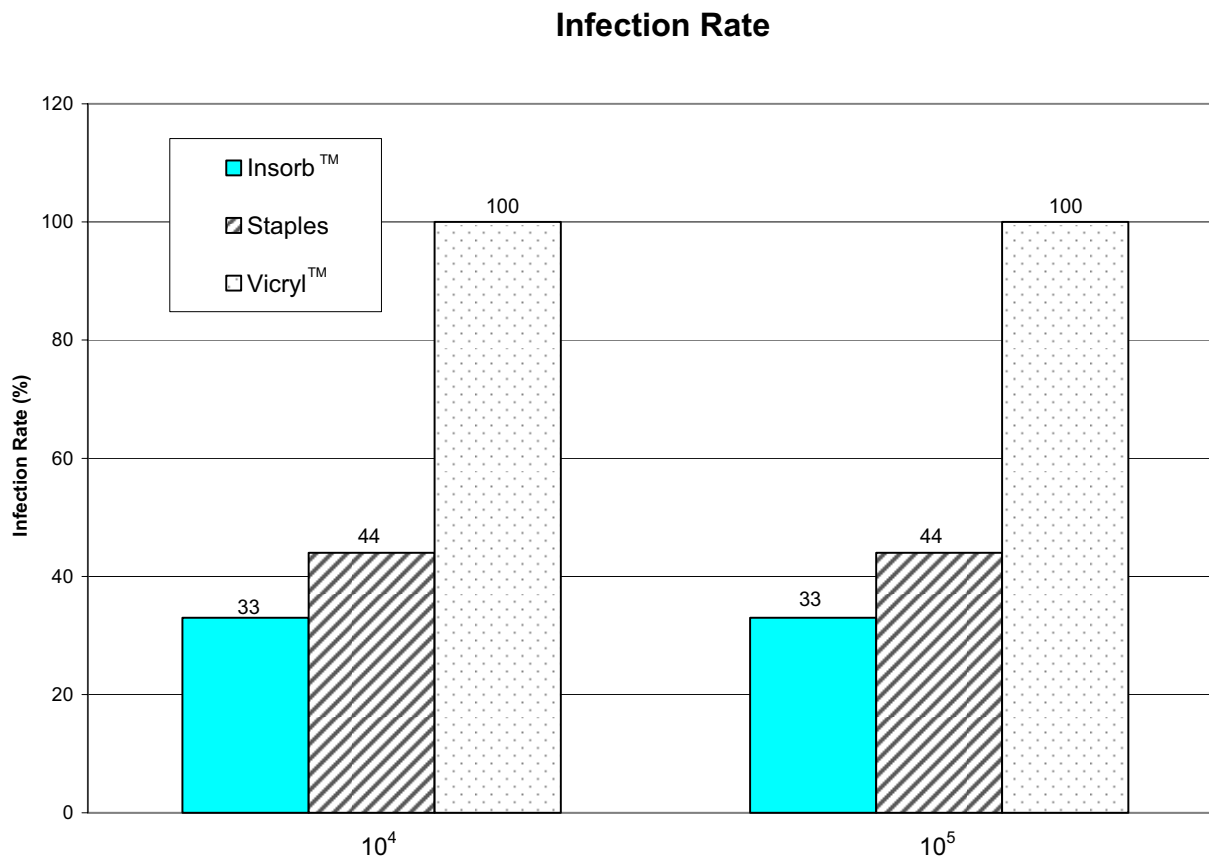


FIGURE 3. Infection rates.

of wound infection, their mechanisms of wound closure were very different. The Insorb™ staple is an absorbable staple that is placed in the subcuticular tissue to hold the wound together without puncturing the epidermis. In contrast, the skin staple is an external, metal staple that penetrates the epidermis on both sides of the incision to provide closure. These external staples have the disadvantages of causing skin irritation and discomfort to the patient and requiring painful removal 7–14 days following closure. The puncture holes in the epidermis may result in unacceptable scarring at the surgical incision.

Another disadvantage of percutaneous metal staples is that the integrity of the epidermis is breached by the puncture of the staples. Thus, external contamination can follow the staple leg from the exter-

nal surface into the subcuticular tissue. Much of the inflammation seen around the staple legs is probably due to localized inflammation caused by skin bacteria. There is also the possibility that if the wound surface is contaminated, the presence of the percutaneous staples could enhance the wound's susceptibility to infection.

A study similar in design to this study was conducted by another research group at the University of Minnesota (Minneapolis, Minnesota).⁶ In their study, they did not contaminate the wounds, although the wounds were not dressed and were exposed to debris and external contaminants. The wounds were assessed on postoperative days 1, 4, 7, 11, 14, 17, 21, 28, 35, and 42 for dehiscence, erythema, swelling, and exudate. In accordance with clinical practice, the metal staples

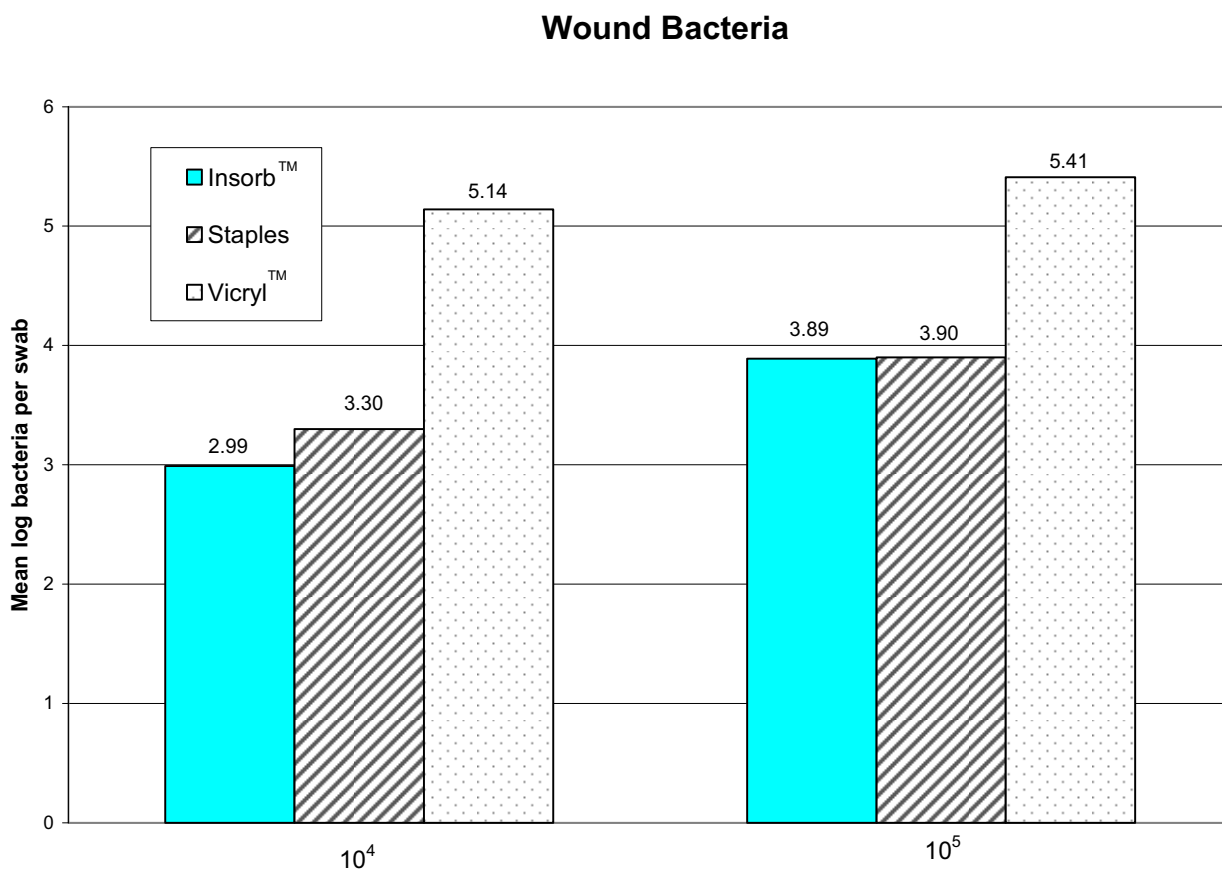


FIGURE 4. Wound bacterial counts.

were removed on day 11. On days 7, 14, 21, and 42, two pigs were euthanized, and the wounds on each pig (one Vicryl™, one metal staple, and two Insorb™) were excised and processed for histological analysis.

Macroscopic assessment documented that the percutaneous metal staples were associated with a severe inflammatory response prior to their removal, whereas the wounds closed with Vicryl™ or Insorb™ showed minimal inflammation. Histopathologic evaluation revealed the lowest tissue inflammation with the Insorb™ staples, compared to Vicryl™ suture or metal staples.

The results obtained in the present study are slightly different than those of the University of Minnesota study. In both studies, the presence of Insorb™ staples in the tissue produced minimal inflammation (Fig. 5).

In contrast, in this study the presence of the percutaneous metal staples did not cause much inflammation in pigskin even when wounds were contaminated (Fig. 6). Unlike the results of Vicryl™ suture in uncontaminated wounds (Minnesota study), when the wounds were contaminated, the presence of Vicryl™ sutures potentiated a severe inflammatory response resulting in an infected wound (Fig. 7).

V. CONCLUSION

The closure of contaminated wounds with the Insorb™ staples was a superior choice to Vicryl™ suture because they had a significantly ($p = 0.009$) lower incidence of infection. In this study, the performance

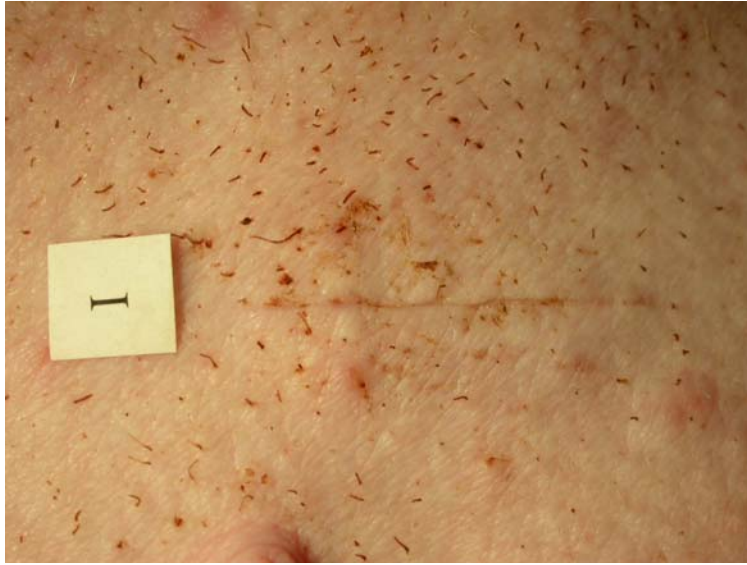

FIGURE 5. Contaminated wounds closed with Insorb™ staples after 7 days in general displayed minimal inflammation. Three of nine wounds in this study became infected.

of Insorb™ staples was similar to that of percutaneous metal staples with respect to the development of wound infection. Other studies have suggested

that the Insorb™ staples may be superior to metal staples with respect to inflammation, pain, and cosmetic outcome.

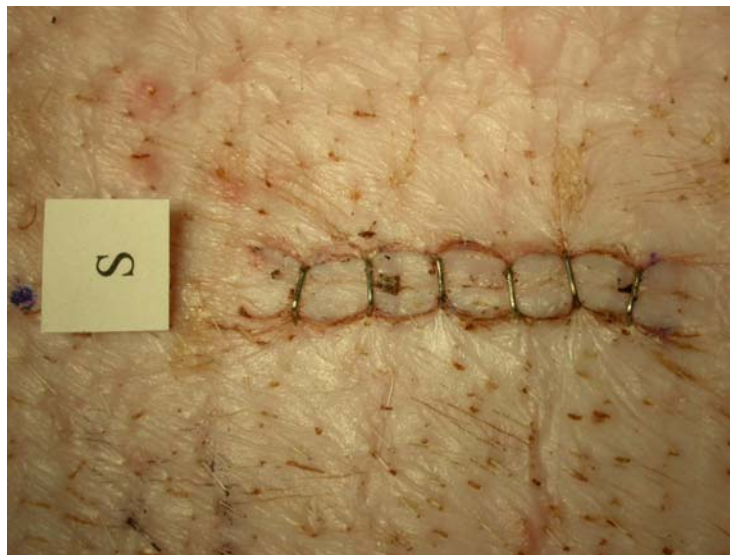


FIGURE 6. Similar to Figure 4, when contaminated wounds were closed with percutaneous metal staples, there was, in general, minimum inflammation at 7 days, and only four of nine wounds became infected.

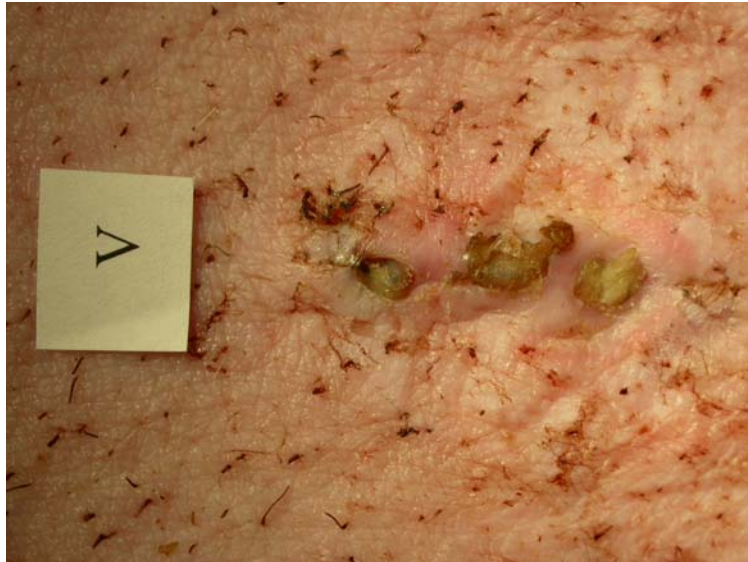

FIGURE 7. In contrast to the other closure devices, all wounds closed with subcuticular Vicryl™ sutures showed intense inflammation at 7 days, and all wounds ($n = 9$) were infected.

REFERENCES

1. Edlich RF, Panek PH, Rodeheaver GT, Turnbull VG, Kurtz LD, Edgerton MT. Physical and chemical configuration of sutures in the development of surgical infection. *Ann Surg.* 1973;177:679–88.
2. Sharp WV, Belden TA, King PH, Teague PC. Suture resistance to infection. *Surgery.* 1982;91:61–3.
3. Rodeheaver GT, Beltran KA, Green CW, Faulkner BC, Stiles BM, Stanimir GW, Traeland H, Fried GM, Brown HC, Edlich RF. Biomechanical and clinical performance of a new synthetic monofilament suture. *J Long-Term Eff Med Implants.* 1996;6:181–96.
4. Pineros-Fernandez A, Drake DB, Rodeheaver PA, Moody DL, Edlich RF, Rodeheaver GT. CAPROSYN™, another major advance in synthetic monofilament absorbable sutures. *J Long Term Eff Med Implants.* 2005;14(5):359–68.
5. Edlich RF, Woodward CR, Rodeheaver GT. Revolutionary advances in skin stapling: a collective review. *J Long Term Eff Med Implants.* 2001;11(1–2): 73–91.
6. Fick JL, Novo RE, Kirchof N. Comparison of gross and histologic tissue responses of skin incisions closed by use of absorbable subcuticular staples, cutaneous metal staples, and polyglactin 910 suture in pigs. *Am J Vet Res.* 2005;66(11):1975–84.

